MOISTURE: THE KEY TO REVITALIZING SKIN INSIDE & OUT

Carroll Zahorsky, M.D.
Kathleen M. Stegman, RN, MA, CDT, CPMA, CLT
O. W. Tawfik, M.D., Ph.D.

Abstract

This study examines the qualitative and quantitative effects of Javani™ skin rejuvenation treatment series on the skin. Javani products are a series of topicals that focus on retaining moisture in the skin using a new form of Micronized Intact Collagen™ that absorbs into the epidermis. These products are applied using the Javani Skin Rejuvenation process, a non-invasive combination therapy with exfoliation, treatment, hydration and maintenance steps. Five healthy male and female subjects received a series of eight Javani facial treatments over an eight-week period (once per week). Photographic and histological evidence is presented along with patient and investigator evaluations. Significant improvements are seen in the epidermis and superficial dermis.

Introduction

The skin functions as a barrier that guards against damage caused by ultraviolet radiation from sunlight, percutaneous absorption of a wide variety of xenobiotics such as chemical residues, air pollution, from desiccation, and from insults by a number of environmental conditions.[7] In providing this protective function, skin itself can be damaged over time, causing undesirable appearance, texture and feel.

At the same time, skin suffers the internal effects of aging due to processes involving collagen-elastin degradation, glycation (protein cross-linking), and free radical-induced injury. This can cause wrinkling of the skin, rough texture, loss of elasticity, and skin cancers.[1,2,3] The resulting internal degradation results in visible effects in the outward appearance of the skin, including discoloration, rough texture, dryness, fine lines and wrinkles.

One of the most critical factors for beautiful, healthy skin is the water-holding capacity and lipidic content of the epidermis and in particular, the stratum corneum.[4] Without sufficient moisture, the epidermis cannot efficiently renew itself through the desquamation process, leading to dry feel, rough texture and buildup of excess stratum corneum. At the same time, the lack of moisture can result in reduced sebum production, which impairs the barrier function of the epidermis. Loss of water also causes destructive alterations in collagen, elastin and skin anatomy, physiology and biochemistry which contribute to degenerative changes seen in aging skin and its barrier function.[8]

"Water is the most powerful anti-aging ingredient of the 21st century"[5]
--Dr. Howard Murad

Moisture is now well accepted as the key to healthy, protected skin. With sufficient moisture, skin is able to regularly renew and to create enough sebum to provide barrier functionality. Skin-damaging external factors are also accepted as contributors to moisture loss from the skin. However, every aesthetic procedure currently available to skin care professionals also takes its share of moisture out of the skin. Few of these procedures take measures to replace that lost moisture. Additionally, few topical products are designed to deliver and hold moisture, opting to use alcohol and glycerin to draw moisture from the dermis to epidermis.

Newer skin rejuvenation products are needed that address the underlying causes of damaged skin, retain moisture, and use safe, painless, healthy means to achieve results comparable to more invasive cosmetic procedures, with less cost.

Javani™ Skin Rejuvenation products are topical preparations that incorporate Micronized Intact Collagen™, a form of Type I collagen that absorbs into the epidermis. The collagen simultaneously delivers moisture to the skin and hydrates, retaining moisture in the epidermis. These products are used in conjunction with the Javani™ Skin Rejuvenation Process, an adaptable form of non-invasive combination therapy with exfoliation, enhancing treatment, hydration, and maintenance steps. This process defines standalone usage of Javani products as well as integration of Javani products with existing cosmetic treatment procedures. In the latter modality, results are enhanced by the hydrating and soothing effects.

This study was designed to examine the short-term effects of a simple Javani treatment on the dermis and epidermis. Qualitative results were recorded in the form of patient and investigator surveys, before/after photography, and moisture measurements were recorded. Histologic examination of skin samples from treated and untreated skin is also performed.

Materials and Methods

Five healthy male and female subjects (aged 57-75, Fitzpatrick type I/II skin) were selected to receive a series of eight Javani Skin Rejuvenation Facial treatments over an eight-week period (once per week). Three of the participants consented to provide biological specimens for later histological examination.

Before the onset of the study, participants were polled for their skin care goals and evaluated by the Investigator to record pre-existing skin conditions. The participants were similarly polled and evaluated after the final procedure. Subjects also were patch tested for bovine collagen allergy as an inclusion criterion for this study. No allergic reactions were noted during the course of this study.

The study procedure consists of a four-step facial application, lasting 25 minutes:

1. Removal of surface contaminants and sebum by cleansing with soap and water (5 min).

2. Infusion of Javani Deep Hydrating Gel into the epidermis using ultrasonic energy with electrical stimulation[1] (15 min; 5 min for forehead, nasal/chin, left cheek, right cheek).

3. Cleanup followed by hand massage of Javani Deep Moisturizing Cream into treatment areas to restore pH and to restore lipids (5 min).

4. Home-based maintenance between treatments by applying Javani Cream twice daily.

During the study participants were asked to observe the following restrictions:

- Application of *any* skin care products other than those provided was forbidden, with the exception of sunscreen of the participant's choice.

- Additional cosmetic treatments were prohibited during the study, without first consulting with the Investigator

- Facial cleansing products were allowed, but required immediate application of Javani Cream immediately after use.

INVESTIGATOR/PATIENT SURVEYS

Participants were asked to rate their skin condition before and after each individual treatment. Investigators were similarly asked to rate the Participants' skin condition before the onset of the study and after completion of the study. These evaluations rated the following three factors on a scale from 1 – 9:

1. Skin feel (dryness), with very dry skin having a score of 1 and a moist skin a score of 9

2. Color, with pale/dull skin scored as 1 vs. healthy/radiant, scored as 9

3. Texture, with rough/hard skin was scored as 1 and smooth/soft skin was scored as 9

4. Fine Lines/Wrinkles, with deep lines scored 1 and shallow/fine lines scored 9.

Each factor was given an individual score and a combined score was recorded for each subject before treatment and immediately following each application.

Patients were also asked to articulate their level of satisfaction with the procedure and any observations they noted.

PHOTOGRAPHIC DATA

Full face photographs were taken before and after each treatment from three angles. Ultraviolet light (UV) photographs were also captured before and after treatment. UV photography is a means to visualize the presence of hydrated skin.

SKIN MOISTURE CONTENT ANALYSIS

Before and after each treatment, epidermal moisture content was determined using a Scalar America contact moisture checker. This instrument measures the moisture content of the epidermis and reports it as a

[1] The DermaWave Ultrasonic/Electrotherapy system provided the ultrasonic energy and electrical stimulation. The device was configured for 2.2MHz operation at 1.5W/cm^2, with electrical stimulation ranging from 10-25V, depending on the patient's comfort level

percentage. Table 1 (taken from the manual) describes how to interpret the return values.

Reading	Indication
45.1 +	Very High
39.1 – 45.0	High Normal
27.1 – 39.0	Mid Normal
22.1 – 27.0	Low Normal
12.1 – 22.0	Low
Below 12.1	Very Low

Table 1. Interpreting Moisture Checker Values

HISTOLOGICAL ANALYSIS

Following the review and signing of the Informed Consent document, subjects were examined by a plastic surgeon. Under local anesthesia, 2 x 3 mm punch biopsies were obtained from three participants for histological examination after the final procedure. One sample was taken from the treatment area (periauricular region) and another sample from an untreated area (neck). Specimens were placed in 10% neutral buffered formalin and delivered to the Surgical Pathology laboratory at the University of Kansas Medical center for processing and histological evaluation.

Tissue specimens from treated and non-treated areas from each individual were subjected to the following analyses:

- Verhoeff's elastic stain (VVG) and trichrome special stains were used to study elastic fiber fragmentation and collagen fibers deposition in each specimen, respectively.

- Immunostains for Collagen types I and III were carried out on the specimens using an automated DAKO autostainer using the DAKO LSAB+ detection.

- Light Microscopy for visualization of overall skin architecture. For each specimen, the pathologist recorded information about epidermal thickness, number of cell layers in the epidermis, nuclear morphology, moisture, and elastic and collagen content, in addition to other pathologic abnormalities if noted.

- The immunohistochemical profiles of the study participants will provide insight concerning the changes in collagen contents for each individual.

Results

SUBJECTIVE FINDINGS

INVESTIGATOR SURVEY

Before the onset of the study, Investigators determined that the participants' skin feel was deficient in feel, color and texture, with moderately deep fine lines and wrinkles. Investigators reported significant improvements in all subjective evaluation areas at the end of the study, as indicated in Table 2, with marked improvements in feel (moisture, color, and texture.

Category	1 2 3 4 5 6 7 8 9		Avg. Pre	Avg. Post
Skin Feel	Dry	Moist	3.0	7.0
Color	Pale	Pink	3.8	6.2
	Dull	Radiant	2.6	7.2
Texture	Rough	Smooth	4.0	6.8
	Hard	Soft	4.2	7.2
Fine Lines	Deep	Fine	4.6	6.8
Wrinkles	Deep	Shallow	3.4	6.2

Table 2. Investigator Subjective Evaluation Results

PARTICIPANT SURVEY

Participants consistently reported immediate improvement in skin feel, color, and texture after individual treatments, as indicated in Figure 1. On average, participants reported a two-point increase in their self-evaluations of each category for any given treatment. Over time, the pre-treatment self-evaluation linearly increased, indicating a cumulative positive benefit in skin color, feel, and texture. At the same time, the post-treatment self-evaluation approached the maximum in each category. The final result indicates an average 4 point gain in each category over the course of the study, nearly double the baseline reading. Note that participant self-evaluation rating data for fine lines/wrinkles were dismissed due to a defect discovered in the survey form.

All study participants wrote comments indicating satisfaction with the results of the treatments, citing comfort of the procedure and the lack of drawbacks or complications. One participant indicated noticeable plumping of the skin to the extent that eyeglasses needed adjustment. Each participant indicated improvements in the depth of fine lines/wrinkles to varying degrees.

EPIDERMAL MOISTURE CONTENT

As indicated in Figure 2, the average baseline moisture reading in all treatment zones was within the "Mid Normal" level. Immediately post-treatment the

moisture levels rose by 10-15% into the "Very High" range, particularly in the forehead region. Over time, pre-treatment moisture levels linearly increased to 10 percentage points higher than pre-study levels, indicating a cumulative moisture benefit to the patients' skin. The cumulative increase in moisture readings indicate hydration occurring in the epidermis and provide some explanation of the immediate plumping observed in the before/after photographs in Figure 3 and Figure 5.

BEFORE/AFTER PHOTOGRAPHY

Before and after treatment photos from alternating study weeks were recorded for all participants. A summary of photographic results are given for two participants (JL in Figure 3 and MM in Figure 5). Noticeable improvements can be seen in color and volume of the skin in both subjects. Skin color clearly moves from reddish to pinkish hues. Note the smoothing of fine lines and wrinkles in the forehead, nasiolabial, and periorbital regions of JL and in the forehead and periorbital regions in MM.

ULTRAVIOLET LIGHT IMAGING

Panel 4 in Figure 3 and Figure 5 reveal the condition of the epidermis under UV light for JL and MM. In general, bright blue areas indicate healthy, well-hydrated skin. Dark spots indicate acne or dry skin, depending on skin type. Purple or reddened areas indicate inflammation.

Note the disappearance of inflammation in MM's right cheek and the uniform hydration present throughout his face post-treatment.

JL initially exhibited several dehydrated areas. At the end of the treatment series, her face showed consistent hydration in all areas, particularly in the cheeks and forehead.

OBJECTIVE FINDINGS

HISTOLOGY

Skin biopsy specimens from three patients were carefully analyzed. Light microscopy was performed to display overall architecture with careful attention to epidermal thickness, layers of cells, nuclear morphology, moisture, collagen and elastin content in the dermis, in addition to any other histopathologic alterations. VVG stain was performed to study elastic fibers content. Trichrome stain, immunostains for Collagen types I and III were also performed to detect alteration in total collagen content as well as types of Collagen. Figure 4 and Figure 6 illustrate the histological results derived from treated and non-treated biopsy samples taken from JL and MM, respectively.

All patients exhibited marked improvements in the stratum corneum, epidermis, dermis following treatment. There was up to 75% decrease in thickness of stratum corneum. In the epidermis, there was noticeable increase in number of cell layers as compared to the non treated samples, additionally, the intercellular spaces was more prominent, suggesting an increase in skin moisture and the nuclei appeared larger with less dense chromatin and had prominent healthy nucleoli. Finally, in the upper dermis, just beneath the epidermal basement membrane, there was significant increase in collagen I and elastic fibers with a marked reduction in collagen III.

Discussion

This study demonstrates that the Javani™ Skin Rejuvenation Process produces significant improvements in the epidermis and dermis using simple procedures and methods.

Histological results indicate more cell layers containing healthier cells. Thinning of the stratum corneum without the use of any aggressive exfoliation methods suggests improved desquamation processes in the epidermis. Increased intercellular spacing and prominent nuclei in basal cells also indicates healthy cell function and account for the improvement in color and the reduction in depth of fine lines and wrinkles.

After 8 weeks of treatment there was clear indication of remodeling of the superficial layers of the dermis in the form of increased density of Collagen I, prominent collagen, and Elastin. These changes also account for the fuller appearance and the reduction in depth of fine lines and wrinkles. Such evidence suggests that with continued application of Javani skin rejuvenation treatments, additional cumulative results may be expected

Clear subjective improvement was reported by clinicians and patients alike in the areas of color, texture, feel, and appearance of fine lines and wrinkles. Additionally, participants were satisfied with the procedures, citing immediate results, pain-free and non-invasive procedure, and uncomplicated maintenance regime.

UV photography suggests deep hydration of the skin, which is corroborated by skin moisture content readings. These readings also suggest a cumulative

hydrating effect and speak to the efficacy of Micronized Intact Collagen as a hydrating agent for the epidermis.

Using Javani skin rejuvenation, results previously reserved for aggressive aesthetic and cosmetic procedures (including fillers, resurfacing, etc.) may be obtained without the loss of moisture, downtime/complications, pain, invasiveness, or risk for the patient. From a purely financial perspective, the cost of a series of eight Javani™ Skin Rejuvenating facials is comparable to a single laser or injectable treatment. In addition, patients do not need a wide range or products applied in a complex regime to maintain their new looks.

For the Clinician, the Javani Skin Rejuvenation Process delivers clear, repeatable results internally and externally, with minimal investment in training, inventory, or machinery. With the flexibility of this process, clinicians can scale the results of existing services by integrating the Javani Skin Rejuvenation process and returning moisture to the skin. For example, a Javani facial package may include a chemical peel, microdermabrasion, or laser resurfacing as the exfoliation step. Aggressive exfoliation would strip away excessive skin cells, leaving healthier looking skin at the expense of increased susceptibility of moisture loss. The exfoliation process itself has no effect on the dermis. By applying the Javani process outlined in this paper post-exfoliation, the results of the treatment will be enhanced, providing benefit to the dermis and epidermis. Other types of treatments may be similarly enhanced.

Javani products and processes offer compelling results without many of the expected drawbacks. For more information on what Javani will do for you, visit http://www.myjavani.com.

Carroll Zahorsky, M.D.
Midwest Medical Aesthetics,
11213 Nall Avenue, Suite 140, Leawood, KS 66211
Tel: 913.327.7175

Kathleen M. Stegman, RN, MA, CDT, CPMA, CLT
Midwest Medical Aesthetics,
11213 Nall Avenue, Suite 140, Leawood, KS 66211
Tel: 913.327.7175

O. W. Tawfik, M.D., Ph.D.
Director, Anatomic and Surgical Pathology,
Department of Pathology and Laboratory Medicine
University of Kansas Medical Center
3901 Rainbow Boulevard, Kansas City, KS 66160-7410
Tel: 913.588.1185
otawfik@kumc.edu

Acknowledgements

We would like to thank IM, VM, MB, MM, and JL for their time and participation in this study. We would like to especially thank IM, MM, and JL for their contributions to histological portion of this study.

References

1. Berneburg, M., Plettenberg, H., Krutmann, J., *Photoaging of human skin*, Photodermatol Photoimmunol Photomed, 2000;16:239-44.

2. Monheit, G.D., Chastain, M.A., *Chemical peels*, Facial Plast. Surg. Clin North Am 2001;9:239-55.

3. Bernstein, E.F., Andersen D., Zelickson, B.D., *Laser resurfacing for dermal photoaging*, Clin Plast Surg 2000;27:221-40

4. Attenborough, D., *Life on Earth*, Little Brown, Boston, 1980.

5. Murad H., Dianne P. L., *Wrinkle free forever*. St. Martin Press, New York, 2004.

6. Gilchrest, B.A., Skin aging and photoaging: an overview. *J. Am. Acad. Dermatol.*, 21,610, 1989.

7. Tagami, H., Hashimoto-Kumasaka, K., and Terui, T., *The stratum corneum as a protective biological membrane of the skin, in Skin: Interface of a Living System Perspective for Skin Care System in the Future*, Tagami H., Parish, J.H., and Ozawa, T., Eds., Elsevier, Amsterdam, 1998, pp.23-37.

8. Denda, M., Influence of dry environment on epidermal function, *J. Dermatol. Sci.*, 24(Suppl 1), S22, 2000

9. Loden, M. et al., Friction, capacitance and transepidermal water loss (TEWL) in dry atopic and normal skin, *Br. J. Dermatol.,* 126, 137, 1992.

10. Denda, M. et al., Stratum Corneum sphingolipids and free amino acids in experimentally-induced scaly skin, *Arch. Dermatol. Res.* 284, 363, 1992

11. Motta, S. et al., Abnormality of water barrier function in psoriasis, *Arch. Dermatol.*, 130, 452, 1994.

12. Pinnagoda, J., Standardization of measurements, in *Bioengineering of the skin: Water and the Stratum Corneum*, Elsner, P. Berardesca, E., and Maibach, H.L., Eds., CRC Press, Boco Raton, Florida, 1994, pp. 59-65.

13. Egawa, M. et al., Effects of exposure of human skin to a dry environment, *Skin Res. Technol.*, 8, 212, 2002.

14. Sato, J. et al., Abrupt decreases in environmental humidity induce abnormalities in permeability barrier homeostasis, *J. Invest. Dermatol.*, 119, 900, 2002.

15. Leveque, J.L. et al., Biophysical characterization of dry facial skin, *J. Soc. Cosmetic Chem.,* 82, 171, 1987.

16. Mackenzie, I.C., *The cellular architecture of the stratum corneum, in Stratum Corneum*, Marks, R. Plewig, G., Eds., Springer, Berlin, 1983, pp. 146-152.

17. Marty, J.P., NMF and cosmetology of cutaneous hydration, *Ann. Dermatol. Venereol.*, 129, 131, 2002.

No financial or other incentives were offered or paid to the Investigators or Participants in this study by the manufacturer of Javani™ products. Clinical staff who performed study procedures were compensated at their official pay rate. The Department of Pathology and Laboratory Medicine at the University of Kansas Medical Center was compensated for cost of the Histological analysis. One DermaWave Ultrasonic/Electrotherapy System was provided for use in this study by Dermawave LLC. All Javani products used in the study were provided free of charge by Kushka Cosmetics, LLC.

Kushka Cosmetics, LLC.
3501 S 4th. Street, Suite B, Leavenworth, KS 66048
Tel: 1.877.797.3666
Fax: 913.682.8182

Javani, Kushka and the Javani logo are trademarks or registered trademarks of Kushka Cosmetics, LLC.
Copyright © 2005 Kushka Cosmetics, LLC.

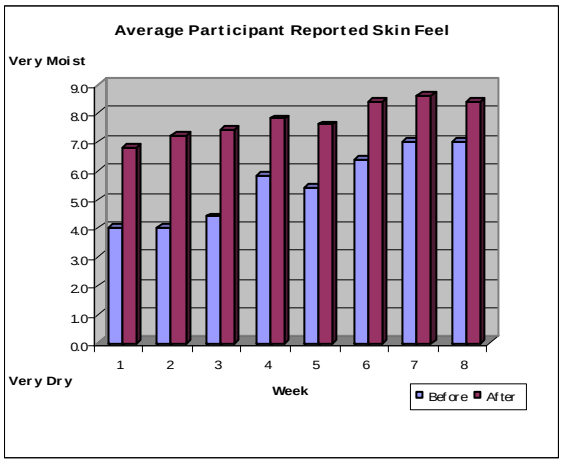

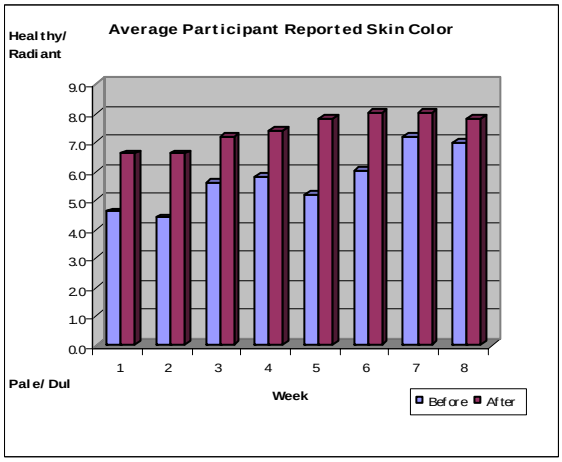

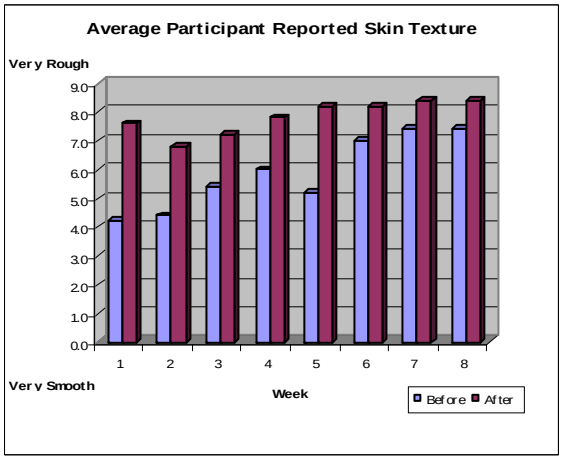

Figure 1. Participant Self-Evaluation Results.
For any given treatment week, participants reported a 2-3 point improvement in each area. Self-evaluation numbers increased over the course of the study, indicating a cumulative benefit over time and participant satisfaction with treatment results.

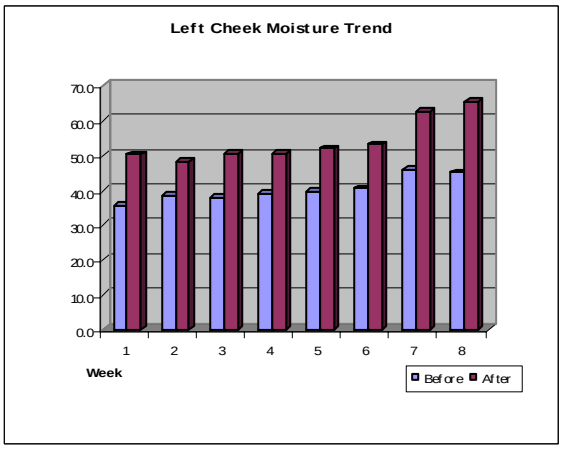

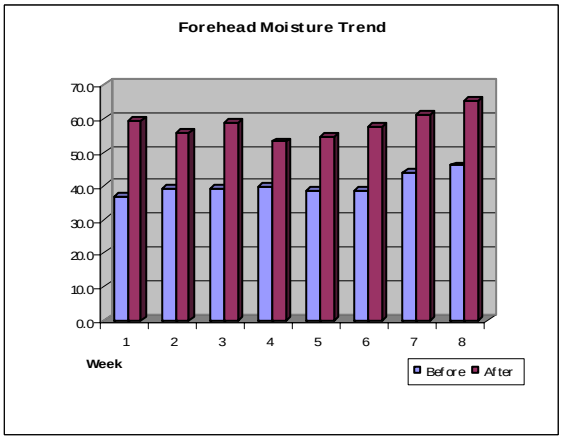

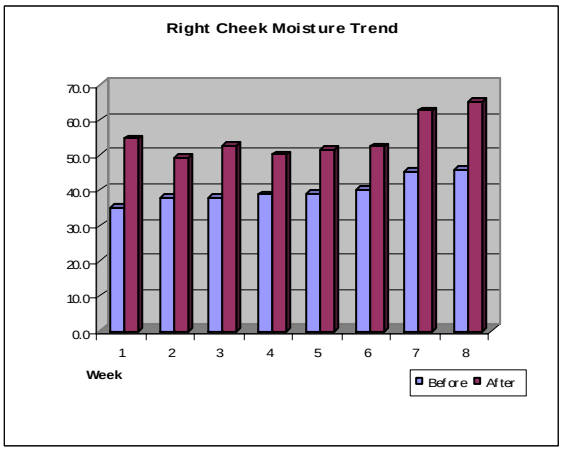

Figure 2. Moisture Checker Readings - Left Cheek, Forehead, Right Cheek.
Pre-treatment moisture content readings for each treatment area steadily rose over the course of the study, indicating a cumulative hydration benefit.

Figure 3. Before/After / Ultraviolet Photograph Set – JL (F/75).
Note the reduction in the depth of fine lines in the periorbital and nasiolabial regions

Pre Treatment **Post Treatment**

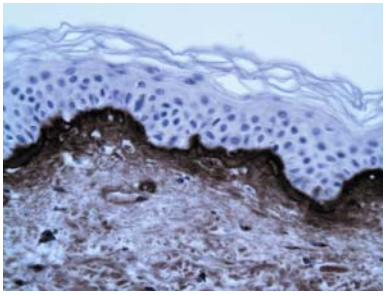

Collagen I (400x)

Type I collagen is desirable, as it forms thick bundles in the dermis, providing strength to the skin. Over time, collagen I degrades, leading to sagging and wrinkling.

Note the increase in the abundance and density of Type I collagen in the superficial dermis.

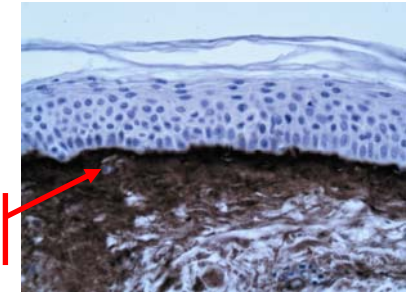

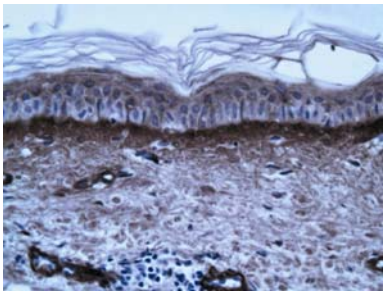

Collagen III (400x)

Type III collagen forms in the dermis as a response to aging, injury or inflammation. The presence of Collagen III indicates these conditions and is undesirable.

Note the reduction in Collagen III in the superficial dermis.

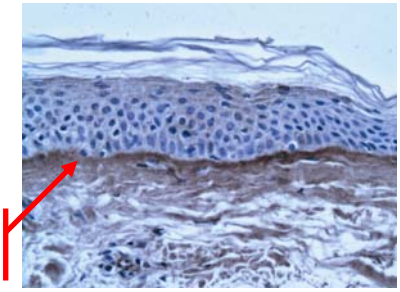

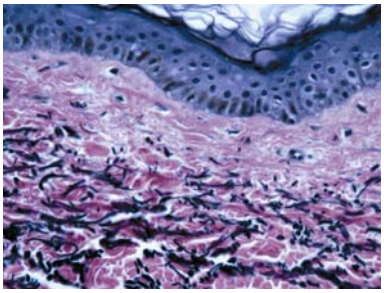

Elastic Stain (400x)

Elastin fibers impart flexibility to the skin. Over time these fibers break down, leading to wrinkling, sagging, and inelasticity of skin.

Note the increase in the abundance and density of Elastin in the superficial dermis.

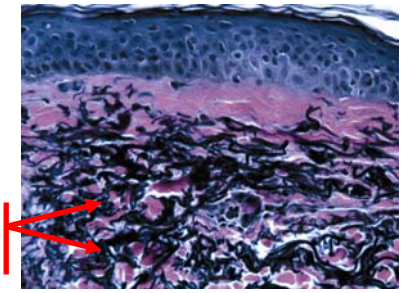

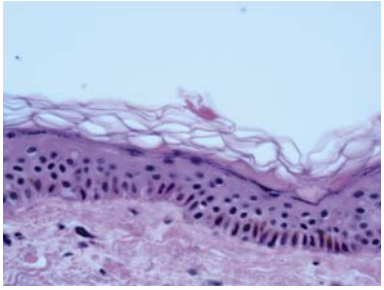

Light Microscope (400x)

Post-treatment, the epidermis shows increased number and thickness of basal skin cell layers, more prominent nuclei and nucleoli, and increased intercellular spacing. Also note the decrease in stratum corneum thickness.

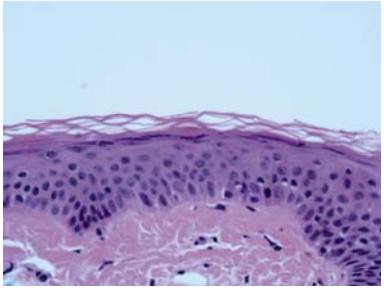

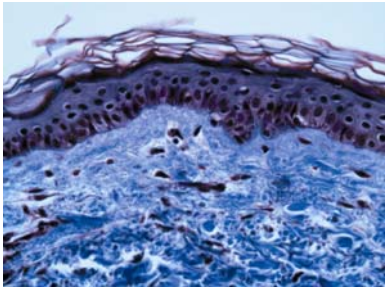

Trichrome (400x)

Trichrome staining indicates the presence of procollagen, precursor to Collagen I. This is desirable, as it suggest fibroblast activity, leading to Collagen production in the dermis.

Note the presence of procollagen (deep blue stains) in the superficial dermis.

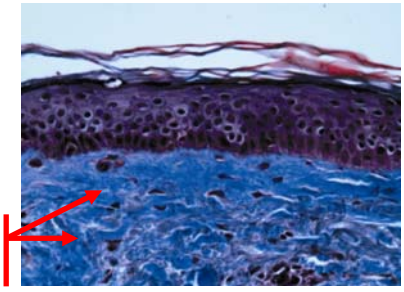

Figure 4. Histological Results - JL (F/75)

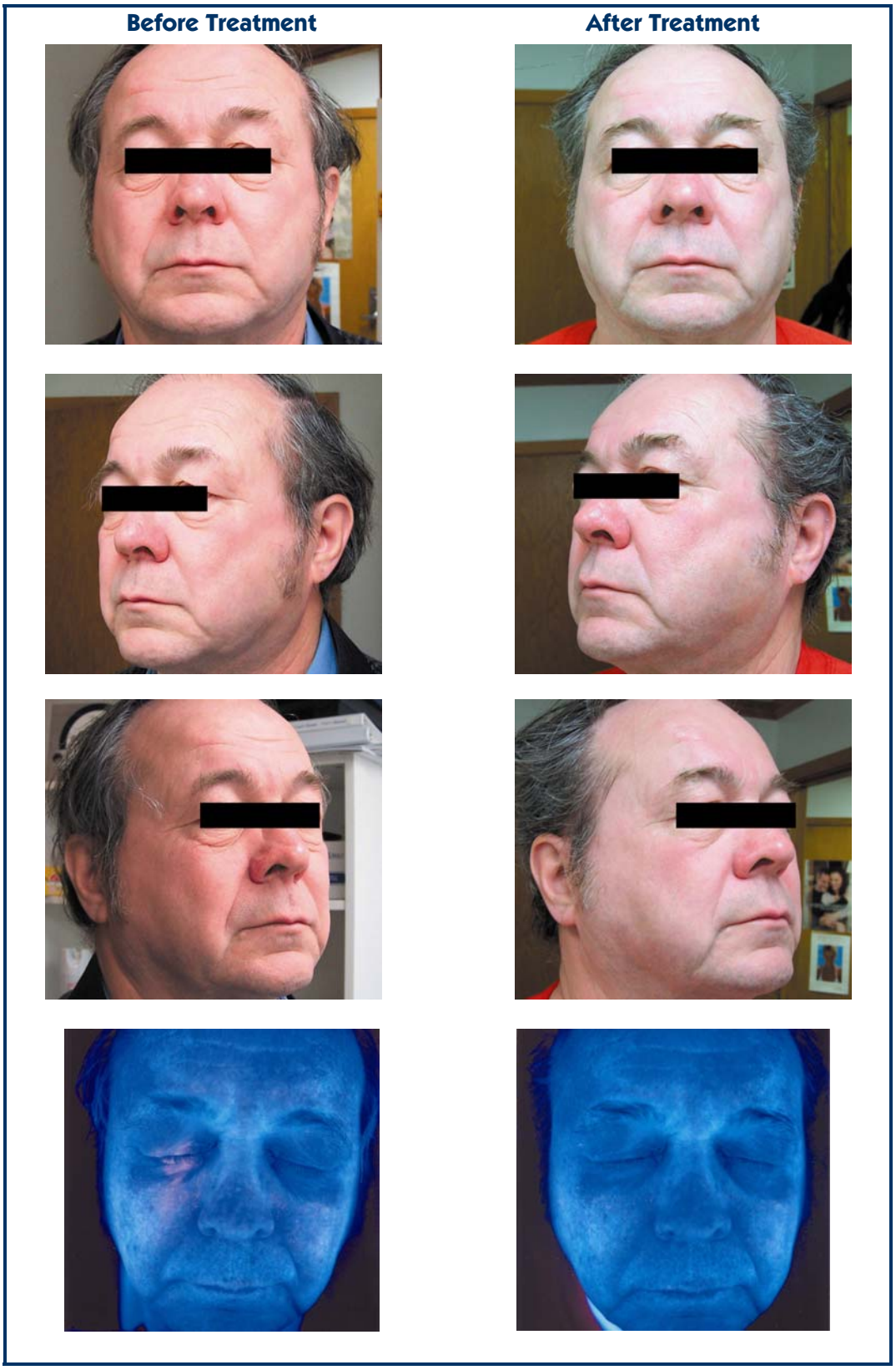

Figure 5. Before / After / Ultraviolet Photograph Set - MM (M/67)
Note the reduction in the depth of fine lines and wrinkles the forehead and periorbital regions

Pre Treatment | **Post Treatment**

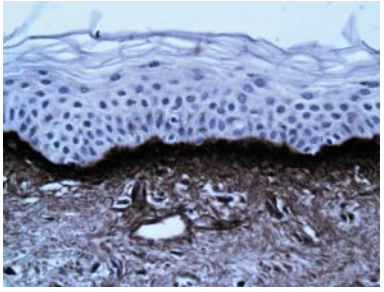

Collagen I (400x)

Type I collagen is desirable, as it forms thick bundles in the dermis, providing strength to the skin. Over time, collagen I degrades, leading to sagging and wrinkling.

Note the increase in the abundance and density of Type I collagen in the superficial dermis.

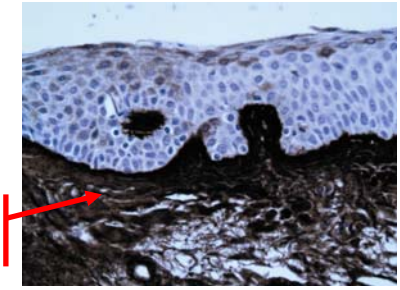

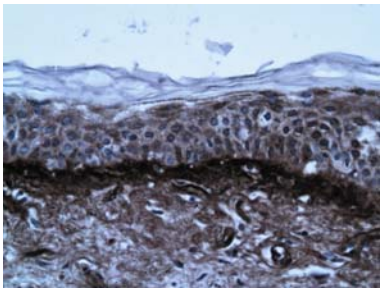

Collagen III (400x)

Type III collagen forms in the dermis as a response to aging, injury or inflammation. The presence of Collagen III indicates these conditions and is undesirable.

Note the reduction in Collagen III in the superficial dermis.

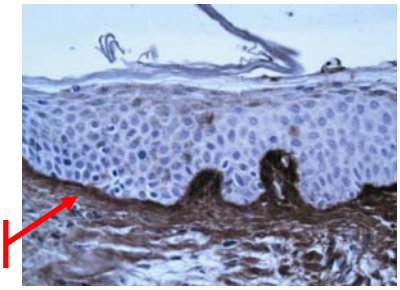

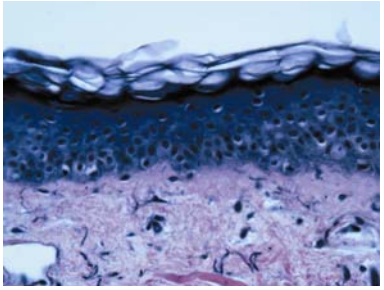

Elastic Stain (400x)

Elastin fibers impart flexibility to the skin. Over time these fibers break down, leading to wrinkling, sagging, and inelasticity of skin.

Note the increase in the abundance and density of Elastin in the superficial dermis.

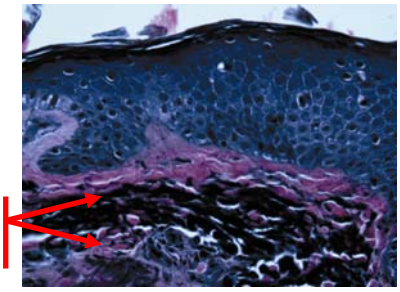

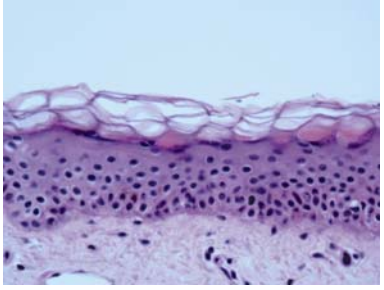

Light Microscope (400x)

Post-treatment, the epidermis shows increased number and thickness of basal skin cell layers, more prominent nuclei and nucleoli, and increased intercellular spacing. Also note the decrease in stratum corneum thickness.

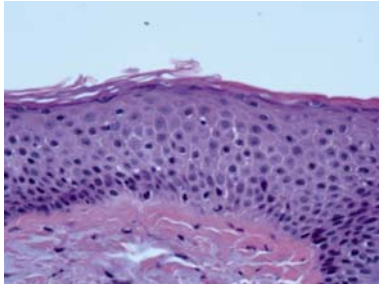

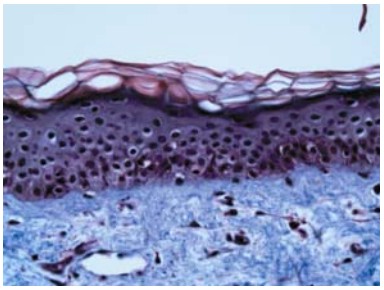

Trichrome (400x)

Trichrome staining indicates the presence of procollagen, precursor to Collagen I. This is desirable, as it suggest fibroblast activity, leading to Collagen production in the dermis.
Note the presence of Procollagen (deep blue stains) in the superficial dermis.

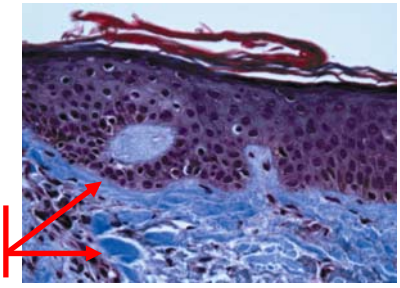

Figure 6. Histological Results - MM (M/67)